

PATIENT

Puck Diaz

SPECIES

Canine

BREED

Cavapoo

SEX

Female Spayed

AGE

11 years

WEIGHT

16.4lbs

INTERPRETED BY

Maggie Machen Lamy,
 DVM, DACVIM
 (Cardiology)

IMAGING PERFORMED BY

Meghan Morse LVT,
 CVT

HOSPITAL NAME

Englewood Cliffs VH

REFERRING VET

Dr. Attanasi

INVOICE

46361

DATE

1/8/26

PRESENTING CLINICAL SIGNS

History: Recheck echo. Doing well. Assess prior to steroids.

-Current medications: Enalapril 3.75mg BID, Spironolactone 12.5mg AM 18.75mg PM, Vetmedin 1 tab BID, Modulis oral 16lb SID.

-Pertinent previous echo findings (11/2024 MML): CVD B2. Moderate MR, moderate to severe LAE, mild LVE, mild TR. LA: 2.8, LV: 3.8.

ECHOCARDIOGRAM FINDINGS

2D, m-mode, color flow and doppler imaging is available. The mitral valve is diffusely thickened with prolapse into the left atrial lumen. There is moderate to severe eccentric mitral regurgitation present. The MR velocity is normal. There is moderate to severe left atrial enlargement. There is mild left ventricular dilation. Left ventricular systolic function is adequate. Mild right atrial and ventricular dilation (subjective). Mild thickening of the tricuspid valve with mild TR. Normal velocity. There is normal systolic flow velocity across the aortic valve. The aortic valve appears trileaflet with normal mobility. The main pulmonary artery is normal in diameter. The pulmonic valve is normal in appearance. No pericardial/pleural effusion or cardiac masses are seen.

CARDIAC CHART

CANINE CARDIAC PARAMETERS	MR VMAX (m/s)	TR VMAX (m/s)	LA/AO (Boon method)	LA/AO (Heart Base; Swe)	FS (%)	EF (%)	EPSS (cm)
NORMAL PARAMETER	4.5-5.5	<2.7	1.3	<1.6	28-40	40-100	<0.6
PATIENT	6.5	2.3	1.8	1.9	45	77	NM
CANINE CARDIAC PARAMETERS	HR (BPM)	AV VMAX (m/s)	PV MAX (m/s)	BODY WEIGHT (kg)	LA 2D short axis Base view (cm)	LVIDd Avg; 2D and m-mode short axis (cm)	LVIDs Avg; 2D and m-mode short axis (cm)
NORMAL PARAMETER	50-100	0.7-1.7	0.7-1.6	BELOW	BELOW	BELOW	BELOW
PATIENT	NM	1.4	1.0	7.4	2.8	4.0	2.2
*Normal chamber parameters expressed as a mean value (SD)				3	1.27 (5.3)	2.46 (2.46)	1.36 (5.5)
BODY WEIGHT DEPENDENT PARAMETERS				5	1.40 (4.5)	2.74 (5.2)	1.60 (4.7)
*Note: All measurements based upon multi-modal images and methods. An average value is reported.				10	1.50 (3.8)	3.27 (3.5)	2.06 (3.1)
				15	1.83 (2.0)	3.71 (2.4)	2.43 (2.1)
				20	2.02 (1.9)	4.14 (2.2)	2.80 (2.0)
Adapted from June Boon, Veterinary Echocardiography, 1998				25	2.18 (2.4)	4.48 (2.9)	3.10 (2.5)
Rishniw M and Hollis NE, J Vet Intern Med 2000; 14:429-435				30	2.33 (3.3)	4.83 (3.9)	3.39 (3.4)
Hansson et al, Vet Rad and Ultrasound 2002				35	2.48 (4.3)	5.17 (5.0)	3.69 (4.5)
Bonagura et al. Echocardiography: principles of interpretation, Vet Clin North Am 15:1177, 1995				40	2.62 (5.2)	5.48 (6.1)	3.96 (5.4)
				50	2.88 (7.1)	6.07 (8.3)	4.46 (7.4)

INTERPRETATION OF THE FINDINGS & FURTHER RECOMMENDATIONS

Chronic degenerative valve disease persists with overall stability, which is great news given the time frame. Moderate to severe MR is similar to previous with stable four chamber dimensions. No additional issues, such as pulmonary hypertension, has developed.

Given these findings, continue three medications as previously recommended. No indication for Lasix, prior to development of clinical signs and/or radiographic evidence of congestion. Continued assessment of progression in the future will help predict long term outcome, however



PATIENT

Puck Diaz

SPECIES

Canine

BREED

Cavapoo

SEX

Female Spayed

AGE

11 years

WEIGHT

16.4lbs

INTERPRETED BY

Maggie Machen Lamy,
 DVM, DACVIM
 (Cardiology)

IMAGING PERFORMED BY

Meghan Morse LVT,
 CVT

HOSPITAL NAME

Englewood Cliffs VH

REFERRING VET

Dr. Attanasi

INVOICE

46361

DATE

1/8/26

prognosis is guarded at this stage (late B2). Unfortunately, the patient will always be at risk for recurrent CHF, development of arrhythmias/LA tear, syncope and/or sudden death in the future. Close monitoring for development of associated clinical signs (development of a cough, labored breathing, exercise intolerance or worsening collapse episodes) is recommended. Monitoring of sleeping breathing rates is recommended as the best way to screen for CHF at home.

Anesthetic risk is considered moderate if needed. Cardiac protective drug choices (opioid/benzodiazepine premedication, propofol or alfaxalone induction, isoflurane gas) are recommended. Pre-oxygenate for 5-10 minutes prior to induction. Monitor for arrhythmias, hypotension, and hypoxia both intra and post-operatively and intervene as necessary. Mild IV fluid restriction is recommended to avoid fluid overload. Avoid heart rate stimulating drugs such as atropine unless clinically indicated.

Omega fatty acid supplementation and mild salt restriction may also be of some long-term benefit.

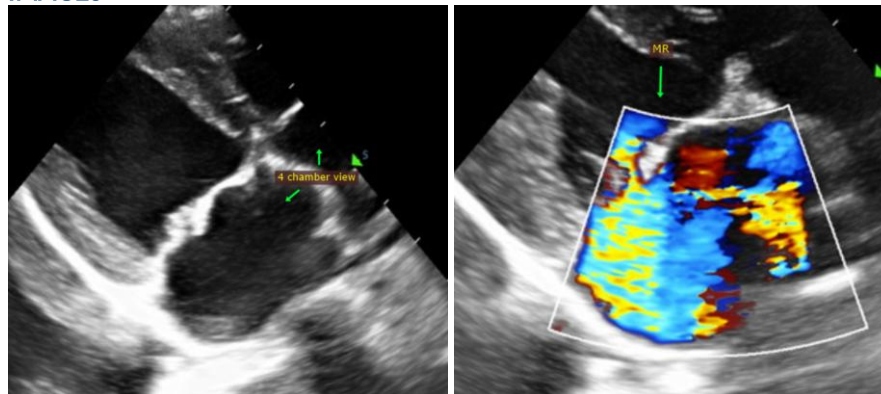
PLAN

A screening BP is recommended every 6 months. Continue Pimobendan, Enalapril and Spironolactone as prescribed.

Monitor renal values and BP every 3-4 months lifelong to ensure tolerance of medications.

Recommend conservative monitoring with a recheck echocardiogram in 6 months, sooner if any development of clinical signs.

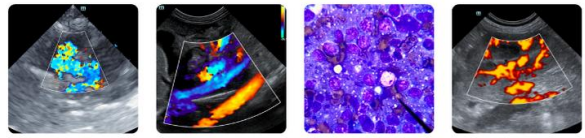
IMAGES



The information and recommendations provided are based on the images presented by the referring veterinarian. No evaluation can be communicated regarding pathology that was not visible in the image/video clips provided.

Thank you for this referral. This report was generated using transcription software, and minor dictation errors may be present. If the clinical or image interpretation does not parallel your findings or if I can be of any further assistance, please contact me.

Maggie Machen Lamy, DVM
 Diplomate of the American College of Veterinary Internal Medicine (Cardiology)
 info@sonopath.com



PATIENT

Puck Diaz

SPECIES

Canine

BREED

Cavapoo

SEX

Female Spayed

AGE

11 years

WEIGHT

16.4lbs

INTERPRETED BY

Maggie Machen Lamy,
DVM, DACVIM
(Cardiology)

**IMAGING
PERFORMED BY**

Meghan Morse LVT,
CVT

HOSPITAL NAME

Englewood Cliffs VH

REFERRING VET

Dr. Attanasi

INVOICE

46361

DATE

1/8/26